

Complex choristoma of the conjunctiva

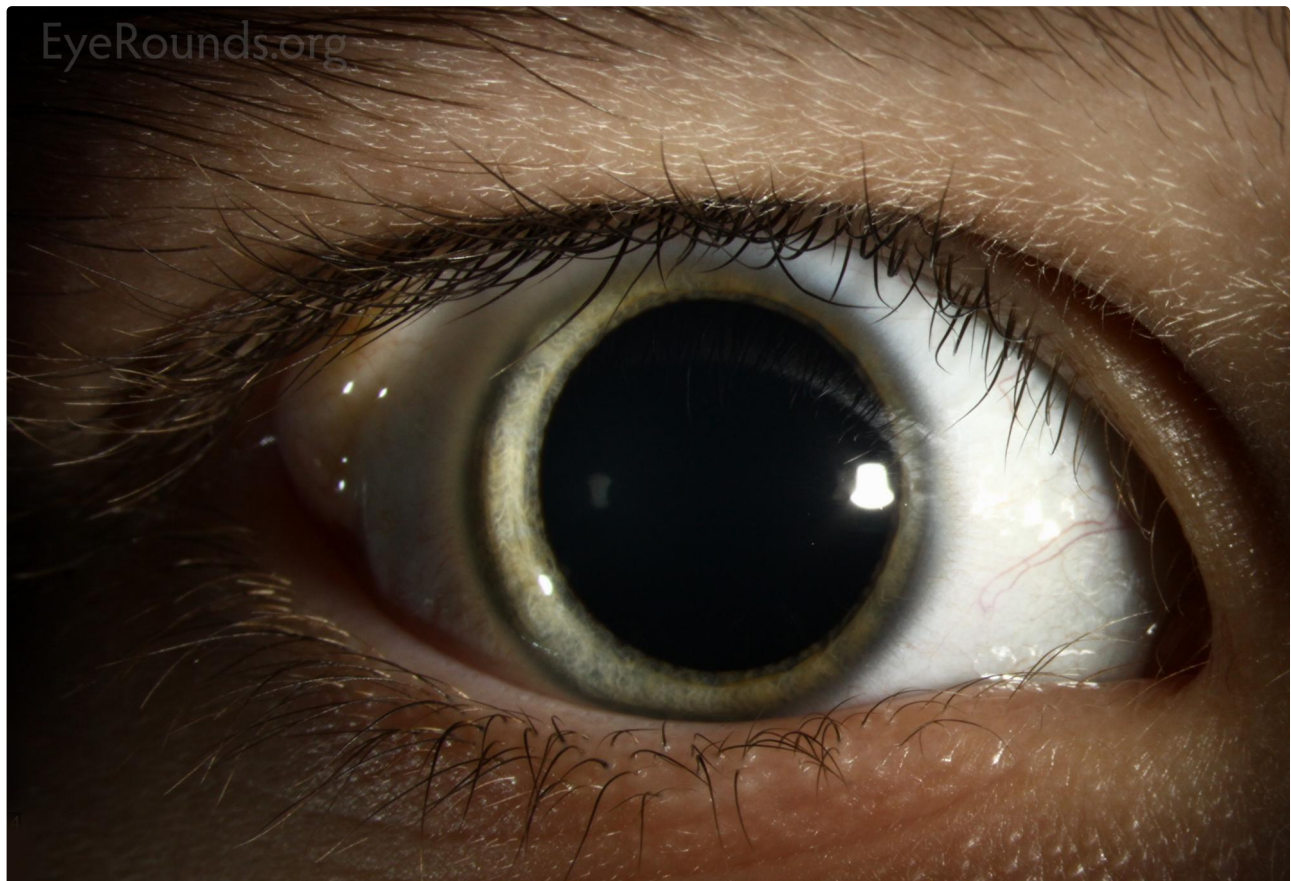Category(ies): Cornea, External Disease

Contributor: [Jesse Vislisel, MD](#)

Photographer: Cindy Montague, CRA

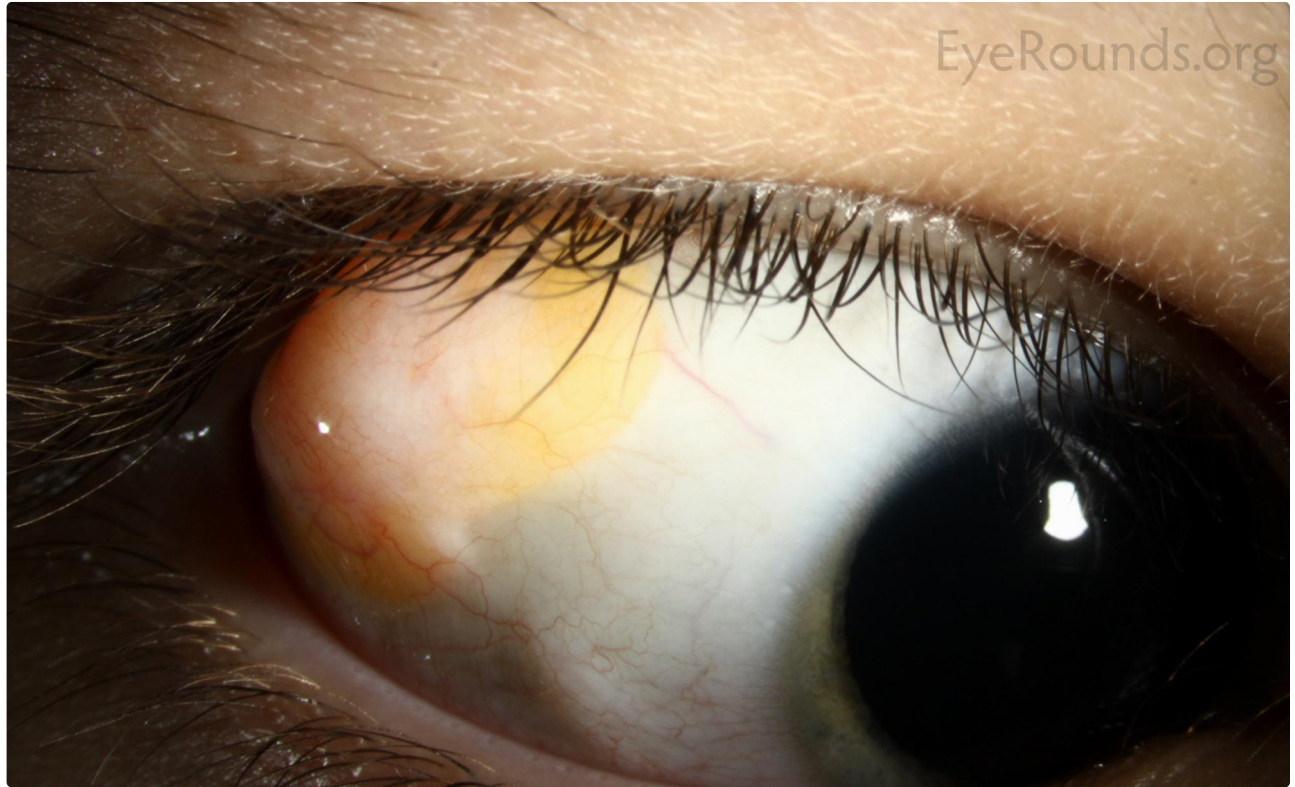

Choristomas are benign, congenital proliferations of normal tissue that is not typically found at the site of the mass. Conjunctival examples include limbal dermoids, lipodermoids, ectopic lacrimal glands, and osseus choristomas. Complex choristomas contain features of multiple types of choristomas. They often cannot be distinguished from dermoids or lipodermoids clinically. This young girl presented with a temporal epibulbar mass that slowly enlarged since birth. Histology of the lesion showed features of both lipodermoid and osseous choristoma (bone formation).



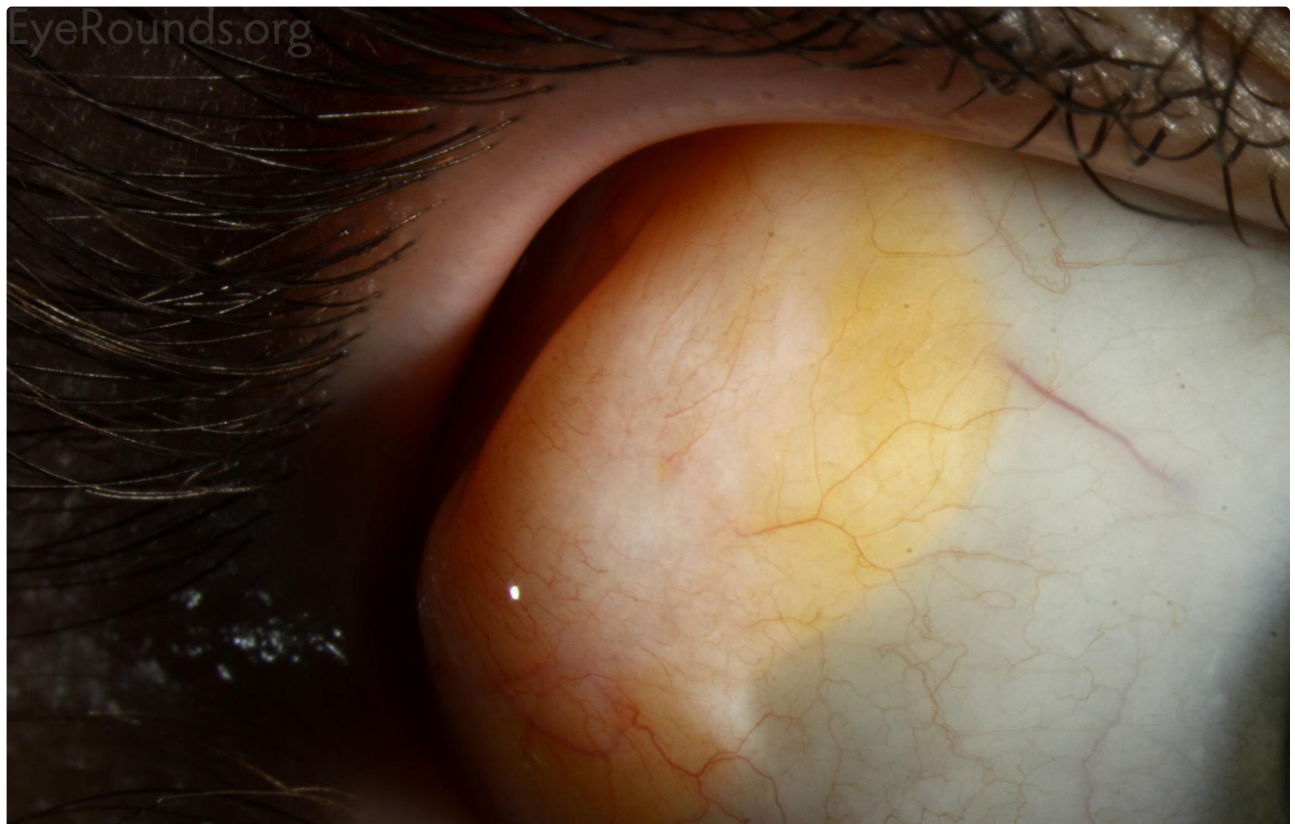
[Enlarge](#)

[Download](#)



[Enlarge](#)

[Download](#)





 [Enlarge](#)

 [Download](#)

Image Permissions:



Ophthalmic Atlas Images by EyeRounds.org, The University of Iowa are licensed under a [Creative Commons Attribution-NonCommercial-NoDerivs 3.0 Unported License](https://creativecommons.org/licenses/by-nc-nd/3.0/).

Address

University of Iowa
Roy J. and Lucille A. Carver College
of Medicine
Department of Ophthalmology and
Visual Sciences
200 Hawkins Drive
Iowa City, IA 52242

[Support Us](#)

Legal

Copyright © 2019 The University of
Iowa. All Rights Reserved
[Report an issue with this page](#)
[Web Privacy Policy](#) |
[Nondiscrimination Statement](#)

Related Links

[Cataract Surgery for Greenhorns](#)
[EyeTransillumination](#)
[Gonioscopy.org](#)
[Iowa Glaucoma Curriculum](#)
[Iowa Wet Lab](#)
[Patient Information](#)
[Stone Rounds](#)
[The Best Hits Bookshelf](#)

EyeRounds Social Media

Follow



Receive notification of new cases,
[sign up here](#)
[Contact Us](#)
[Submit a Suggestion](#)